



PATIENT

Nelly Ness

SPECIES

Canine

BREED

Miniature Poodle

SEX

FS

AGE

7yr

WEIGHT

14lb

PRESENTING CLINICAL SIGNS

P presented BRA with a body condition score of 4/5, Grade 3/6 L sided heart murmur but not heard on the R side as well, MM pink, Heavy calc on remaining teeth, possible syncopal episode. ABNORMAL Labwork Values Lipase 907 otherwise unremarkable lab results.

Current Medications None

Radiographic Findings Radiographs to follow

Notes to Specialist (if any) VDIC report: ovoid soft tissue opaque mass effect within the craniodorsal abdomen in lateral views, caudal to stomach and cranial to one of the kidneys, in the region of the head of the spleen, adrenal glands, and kidneys. The structure is not definitively identified in the VD view.

ULTRASONOGRAPHIC EXAMINATION OF THE ABDOMEN

Urinary System

The urinary bladder, trigone, cystourethral junction, and visible pelvic urethra to a depth of 3 cm exhibited normal thickness and tone. Anechoic urine was present in the lumen with no evidence of urine/lumen sediment, mineral, or calculi. The ureteral papillae were normal. The ureters were not visible which is normal. No evidence of inflammatory or neoplastic changes was noted.

Normal size and margination were present in the kidneys. A normal 1:3 cortex / medulla ratio and normal corticomedullary definition were maintained. The echogenicity of the cortex was similar to or slightly less than normal liver parenchyma while the medulla echogenicity was hypoechoic to the cortex with no evidence of pelvic dilation. The left kidney measured 4.2 cm in length. The right kidney measured 4.3 cm in length.

The area of the aortic trifurcation was free of pathology.

INTERPRETED BY

R. McKenzie Daniel,
DVM, DABVP
(Canine and Feline)

Adrenal Glands

The left adrenal gland was uniform in size and contour with a uniformly hypoechoic parenchyma. The left adrenal gland measured 0.52 cm width at the caudal pole. The right adrenal gland was uniform in size and contour with a uniformly hypoechoic parenchyma. The right adrenal gland measured 0.56 cm width at the caudal pole.

IMAGING PERFORMED BY

Sara Hansen

Spleen

The spleen exhibited a finely textured and homogenous parenchyma which was hyperechoic to the liver and renal cortical parenchyma. The capsule was smooth and regular without apparent expansion. The splenic vasculature at the hilus was normal in volume with no evidence of congestion or thrombosis. Acute to chronic inflammatory, neoplastic, or benign parenchyma changes were not noted.

HOSPITAL NAME

Four Corners Animal
Hospital

Liver/Gallbladder

The liver presented mildly enlarged in size. The parenchyma of the liver was subjectively normal in echogenicity compared to the spleen and renal cortices. The liver parenchyma was uniform with a mildly coarse echotexture. The capsule of the liver was symmetrically rounded to mildly swollen in margination. The hepatic and portal vasculature were normal in appearance without signs of congestion. The gallbladder was non-distended in size with primarily anechoic luminal content. The cystic and common bile ducts were normal.

REFERRING VET

Dr Anderson

INVOICE
24535

DATE

04/20/2026



PATIENT

Nelly Ness

SPECIES

Canine

BREED

Miniature Poodle

SEX

FS

AGE

7yr

WEIGHT

14lb

INTERPRETED BY

R. McKenzie Daniel,
DVM, DABVP
(Canine and Feline)

IMAGING PERFORMED BY

Sara Hansen

HOSPITAL NAME

Four Corners Animal
Hospital

REFERRING VET

Dr Anderson

INVOICE
24535

DATE
04/20/2026

Gastrointestinal

The stomach presented intact wall layering with a normal wall layer ratio. The lumen of the stomach contained mild hyperechoic non-shadowing ingesta with no signs of ileus, obstruction or foreign material.

The small intestine presented intact wall layering with 1:3 muscularis/mucosa ratio. The lumen of the small intestine was empty with no signs of mechanical/metabolic ileus, obstruction or foreign material.

Normal visible colon wall layers were present with apparent formed feces in lumen.

Pancreas

The parenchyma of the right pancreas was hyperechoic to adjacent omental fat with diffuse parenchyma remodeling. The capsule of the pancreas was mildly asymmetrical in contour without evidence of peripancreatic inflammation. These changes may suggest chronic inflammation, fibrosis, or saponification if previous history of pancreatitis. No overt signs of pancreatic neoplasia.

Free Abdomen

No omental masses, overt lymphadenopathy or peritoneal effusion was present.

ULTRASONOGRAPHIC FINDINGS

Primary

- Mild non-congested hepatomegaly- benign
- Sonographically normal spleen
- Normal gastrointestinal tract with mild gastric ingesta -consistent with food echogenicity
- Normal bilateral adrenal glands
- Normal kidneys
- Mild chronic pancreatitis /pancreatic fibrosis

INTERPRETATION OF THE FINDINGS & FURTHER RECOMMENDATIONS

No evidence of intra-abdominal mass or neoplastic criteria. Correlation with a spec cPL if clinical signs consistent with chronic pancreatitis are non-reported or arise. Monitoring of liver enzymes for evidence of emerging hepatopathy is recommended, although the overall mild hepatomegaly is consistent with benign criteria.

Given possible syncopal episode, three view chest radiographs and screening echocardiogram may be considered.



PATIENT

Nelly Ness

SPECIES

Canine

BREED

Miniature Poodle

SEX

FS

AGE

7yr

WEIGHT

14lb

INTERPRETED BY

R. McKenzie Daniel,
 DVM, DABVP
 (Canine and Feline)

IMAGING PERFORMED BY

Sara Hansen

HOSPITAL NAME

Four Corners Animal
 Hospital

REFERRING VET

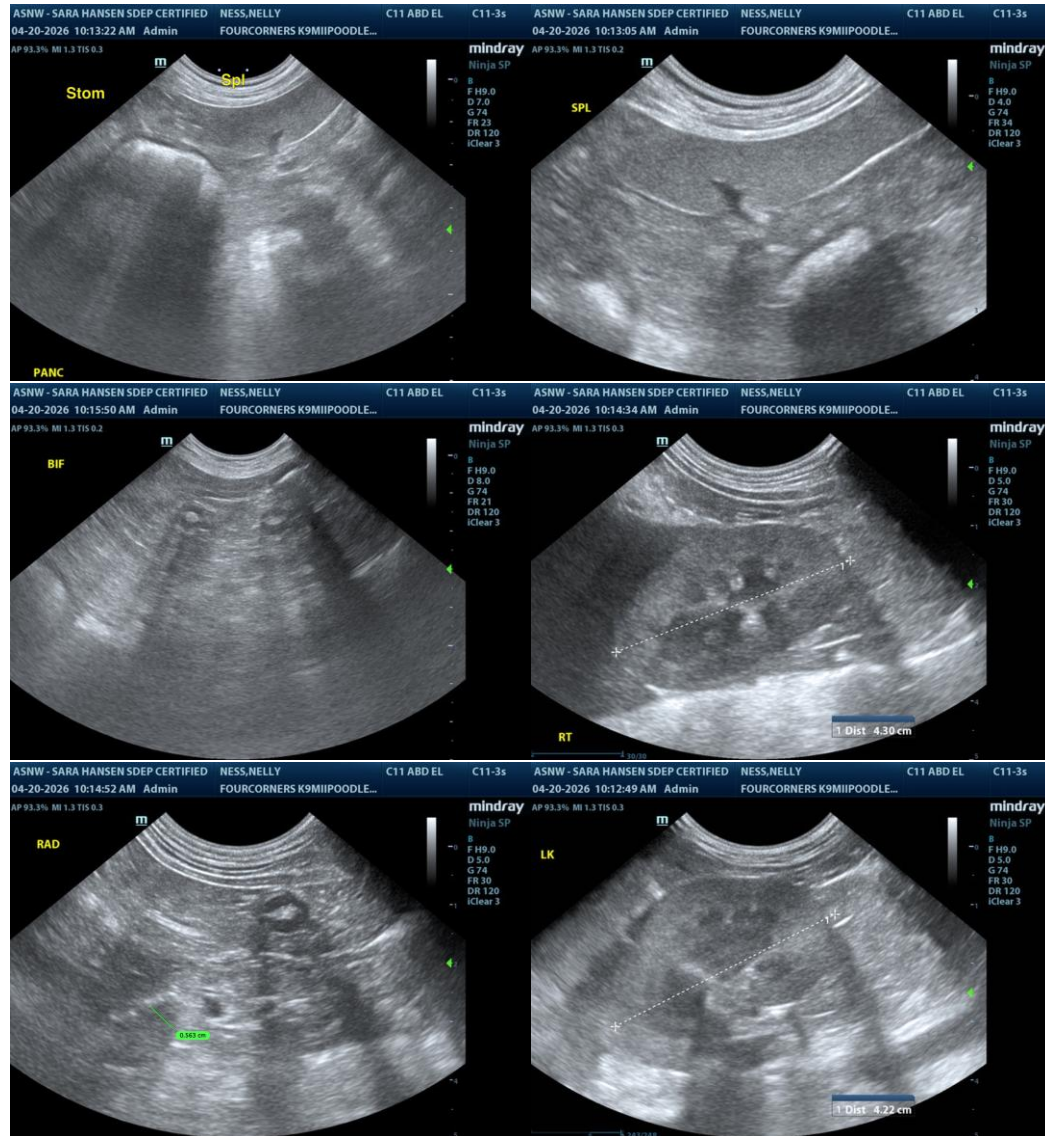
Dr Anderson

INVOICE

24535

DATE

04/20/2026





PATIENT

Nelly Ness

SPECIES

Canine

BREED

Miniature Poodle

SEX

FS

AGE

7yr

WEIGHT

14lb

INTERPRETED BY

R. McKenzie Daniel,
 DVM, DABVP
 (Canine and Feline)

IMAGING PERFORMED BY

Sara Hansen

HOSPITAL NAME

Four Corners Animal
 Hospital

REFERRING VET

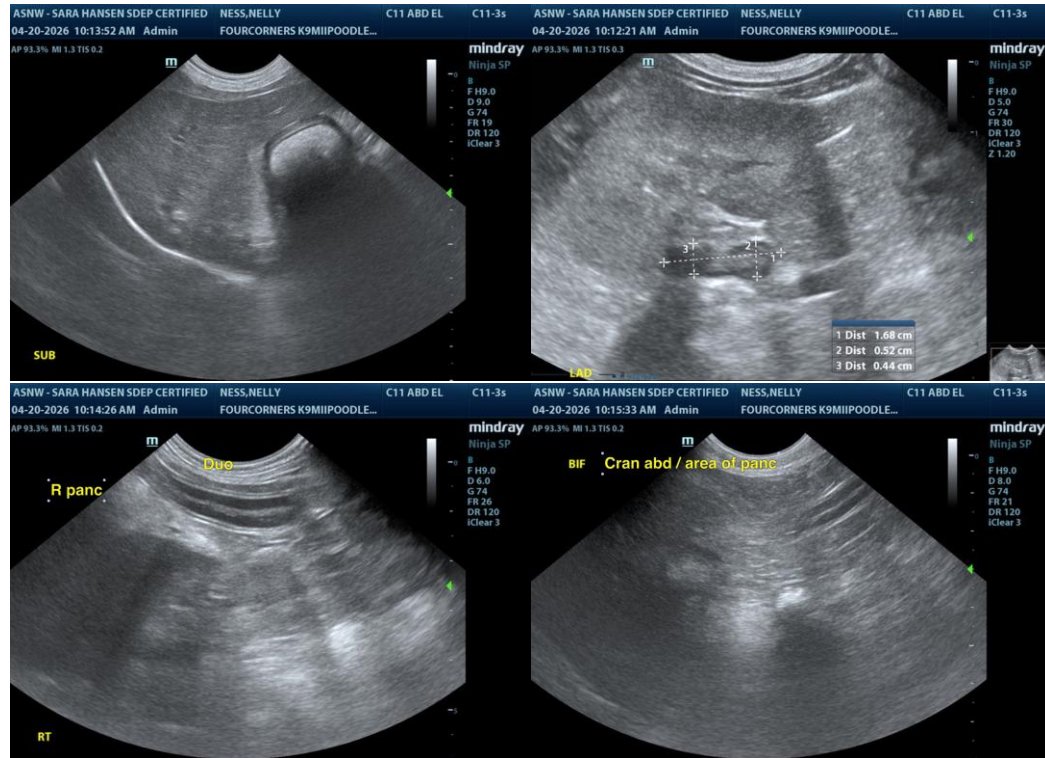
Dr Anderson

INVOICE

24535

DATE

04/20/2026



The information and recommendations provided are based on the images presented by the referring veterinarian/sonographer. No evaluation can be communicated regarding pathology that was not visible in the image/video clips provided.

Thank you for this referral. If the clinical or image interpretation does not parallel your findings or if I can be of any further assistance, please contact me.

R. McKenzie Daniel, DVM, DABVP (Canine/Feline Practice)
info@sonopath.com